



PATIENT

Sophie Krietz

SPECIES

Canine

BREED

Dachshund

SEX

Female Spayed

AGE

14 years

WEIGHT

11.7lbs

INTERPRETED BY

Maggie Machen
 Lamy, DVM, DACVIM
 (Cardiology)

IMAGING PERFORMED BY

Jenna Walsh, CVT

HOSPITAL NAME

VCA Westmoreland
 Animal Hospital

REFERRING VET

Dr. Sullivan

INVOICE

23975

DATE

5/2/22

PRESENTING CLINICAL SIGNS

History: Presented for increased coughing and possible syncopal episodes. Grade 5/6, systolic heart murmur. Loudest over the left thoracic wall. Palpable fluid wave on abdominal palpation, but no free fluid visible on brief US scan. hepatomegaly, pendulous abd, increased BVS in all lung fields, head tremors and borderline collapsing episodes, no focal or petite mal seizure syncope weakness due to heart disease or suspected HAC, last BP done 01/04/22 100mmHg.

-Current medications; Hydrocodone.

-Abnormal PE/Chem/CBC/UA Results: alt-362, alpk-505, BUN-88, Creatinine-3.1, BUN/CREAT RATIO 28, Precision PSL 287.

-CXR report (AIS): Mild LAE, no CHF.

ELECTROCARDIOGRAPHIC FINDINGS *Note: Single lead ECGs are evaluated as a rhythm strip.

Morphology/MEA cannot be definitively commented on.

A single lead ECG is available; 50mm/s, 5mm/mV. The average heart rate is 188bpm with a largely rhythm. The rhythm is sinus in origin, with a p for every QRS complex and vice versa. The P and QRS morphologies are positive. No ectopic beats, pauses or dysrhythmias observed.

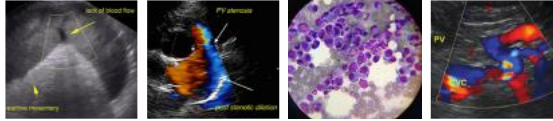
ECG diagnosis: Normal sinus tachycardia.

ECHOCARDIOGRAM FINDINGS

2D, m-mode, color flow and doppler imaging is available. Mild diffuse thickening of mitral valve leaflets with no prolapse into the left atrial lumen. Trace/mild eccentric mitral regurgitation with mild left atrial dilation. Normal MR velocity. Normal to decreased LV dimension with evidence of pseudohypertrophy. The tricuspid valve appears normal with mild tricuspid regurgitation. Velocity consistent with early pulmonary hypertension. Normal right atrial and ventricular diameter and morphology. The pulmonic and aortic valves are normal in morphology and mobility. Mildly elevated flow velocity through both the aorta and pulmonary artery. No obvious aortic or pulmonic insufficiency. No pericardial or pleural effusion noted. No obvious cardiac masses.

CARDIAC CHART

CANINE CARDIAC PARAMETERS	MR VMAX (m/s)	TR VMAX (m/s)	LA/AO (Boon method)	LA/AO (Heart Base; Swe)	FS (%)	EF (%)	EPSS (cm)
NORMAL PARAMETER	4.5-5.5	<2.7	1.3	<1.6	28-40	40-100	<0.6
PATIENT	5.4	3.2	1.4	1.2			0.1
CANINE CARDIAC PARAMETERS	HR (BPM)	AV VMAX (m/s)	PV MAX (m/s)	BODY WEIGHT (kg)	LA 2D short axis Base view (cm)	LVIDd Avg; 2D and m-mode short axis (cm)	LVIDs Avg; 2D and m-mode short axis (cm)
NORMAL PARAMETER	50-100	0.7-1.7	0.7-1.6	BELOW	BELOW	BELOW	BELOW
PATIENT	NM	2.5	2.4	5.3	1.66		
*Normal chamber parameters expressed as a mean value (SD)				3	1.27 (5.3)	2.46 (2.46)	1.36 (5.5)
BODY WEIGHT DEPENDENT PARAMETERS				5	1.40 (4.5)	2.74 (5.2)	1.60 (4.7)
				10	1.50 (3.8)	3.27 (3.5)	2.06 (3.1)



PATIENT

Sophie Krietz

SPECIES

Canine

BREED

Dachshund

SEX

Female Spayed

AGE

14 years

WEIGHT

11.7lbs

INTERPRETED BY

Maggie Machen
Lamy, DVM, DACVIM
(Cardiology)

IMAGING PERFORMED BY

Jenna Walsh, CVT

HOSPITAL NAME

VCA Westmoreland
Animal Hospital

REFERRING VET

Dr. Sullivan

INVOICE

23975

DATE

5/2/22

Adapted from June Boon, Veterinary Echocardiography, 1998 Rishniw M and Hollis NE, J Vet Intern Med 2000; 14:429-435 Hansson et al, Vet Rad and Ultrasound 2002 Bonagura et al. Echocardiography: principles of interpretation, Vet Clin North Am 15:1177, 1995	15	1.83 (2.0)	3.71 (2.4)	2.43 (2.1)
	20	2.02 (1.9)	4.14 (2.2)	2.80 (2.0)
	25	2.18 (2.4)	4.48 (2.9)	3.10 (2.5)
	30	2.33 (3.3)	4.83 (3.9)	3.39 (3.4)
	35	2.48 (4.3)	5.17 (5.0)	3.69 (4.5)
	40	2.62 (5.2)	5.48 (6.1)	3.96 (5.4)
	50	2.88 (7.1)	6.07 (8.3)	4.46 (7.4)

INTERPRETATION OF THE FINDINGS & FURTHER RECOMMENDATIONS

Chronic degenerative valve disease causing mild mitral and tricuspid regurgitation. Lack of significant left atrial enlargement indicates the current risk for complication is low. **My suspicion in this case is the murmur is more prevalent due to increase flow velocity through both great vessels.** This commonly occurs with dehydration as is noted in the history. Finally, the left ventricle appears volume underloaded, which also supports volume depletion. No additional issues are noted in this study. The ECG is unremarkable with a normal sinus tachycardia.

Given these findings, no cardiac medications are clearly indicated. The cough and syncope are unlikely to be related to structural disease. Primary respiratory disease is more likely and further treatment/work up may be warranted. Additionally, the BP should be reassessed as hypotension is considered unlikely in this patient. Assessment of progression in the future will help predict long term prognosis, which is highly variable at this stage (B1). Omega fatty acid supplementation and mild salt restriction may be of some long-term benefit. Monitor for development of a cough, labored breathing, exercise intolerance or collapse episodes.

Anesthetic risk is considered mild if needed. Cardiac protective drug choices (opioid/benzodiazepine premedication, propofol or alfaxalone induction, isoflurane gas) are recommended. Pre-oxygenate for 5-10 minutes prior to induction. Monitor for arrhythmias, hypotension, and hypoxia both intra and post-operatively and intervene as necessary. Mild IV fluid restriction is recommended to avoid fluid overload. Avoid heart rate stimulating drugs such as atropine unless clinically indicated.

PLAN

No medications are indicated. Address primary respiratory causes of coughing. Reassess cardiac dimensions and function once BP and volume status have been reassessed/addressed.

Recommend conservative monitoring with a recheck echocardiogram in 6 months, sooner if any development of clinical signs.



PATIENT

Sophie Krietz

SPECIES

Canine

BREED

Dachshund

SEX

Female Spayed

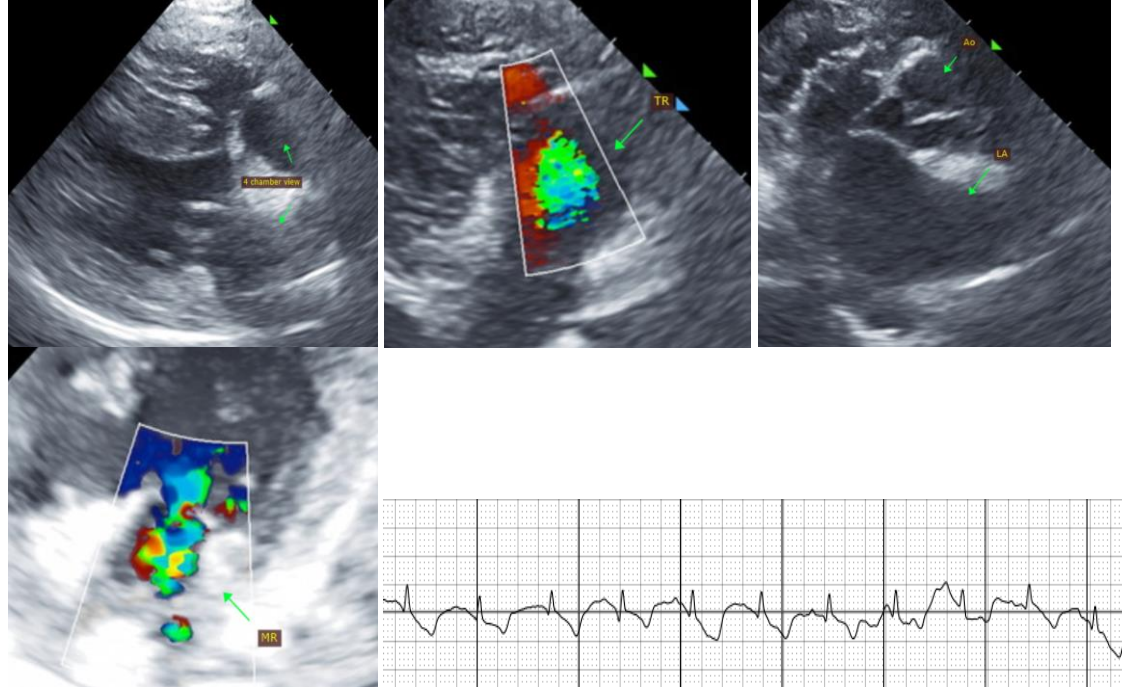
AGE

14 years

WEIGHT

11.7lbs

IMAGES



INTERPRETED BY

Maggie Machen
Lamy, DVM, DACVIM
(Cardiology)

IMAGING PERFORMED BY

Jenna Walsh, CVT

HOSPITAL NAME

VCA Westmoreland
Animal Hospital

REFERRING VET

Dr. Sullivan

INVOICE

23975

DATE

5/2/22

The information and recommendations provided are based on the images presented by the referring veterinarian. No evaluation can be communicated regarding pathology that was not visible in the image/video clips provided.

Thank you for this referral. This report was generated using transcription software, and minor dictation errors may be present. If the clinical or image interpretation does not parallel your findings or if I can be of any further assistance, please contact me.

Maggie Machen Lamy, DVM
Diplomate of the American College of Veterinary Internal Medicine (Cardiology)
info@sonopath.com